

## Case Report

# A Patient with Bluish-Purple lower Extremity Following Robotic Prostatectomy

 Ryan N Qasawa<sup>1\*</sup> and Sachinder S Hans<sup>2</sup>
<sup>1</sup>General Surgery Resident, Henry Ford Macomb Hospital, Clinton Township, Michigan, USA

<sup>2</sup>Vascular Surgeon, Henry Ford Macomb Hospital, Clinton Township, Michigan, USA

## Abstract

**Background:** A patient with a discolored, painful, swollen limb is a concerning clinical finding with a worrisome differential diagnosis. Such findings presenting themselves shortly after another surgical procedure may alter the differential diagnosis, requiring specifics regarding the nature of the procedure as well as detailed pertinent anatomy. This is a case of a 66-year-old male who presented with a bluish-purple lower extremity following a robotic prostatectomy.

**Case presentation:** A 66-year-old male underwent a robot-assisted radical prostatectomy with bilateral pelvic lymphadenectomy. Bleeding was noted in the left pelvis during lymphadenectomy, which was repaired by the surgeon in a figure-of-eight fashion. After hemostasis was achieved, the operation was completed, and the patient was sent to recovery. Shortly after arriving to recovery, patient complained of left lower extremity swelling and paresthesias. He denied any pain. He was sent to the intensive care unit for close monitoring, where he developed pain and blue discoloration of his entire left lower extremity. A CTV demonstrated left external iliac vein thrombosis. He was taken to the operating room by Vascular Surgery where an external iliac vein injury was noted. Limited exposure of the injury required division of the hypogastric artery. The injured segment was resected, and a PTFE interposition graft was performed utilizing a single limb from a bifurcation graft. Patient's pre-operative findings were significantly improved post-operatively and it was discharged on post-operative day 12 on 6 months of Apixiban. Outpatient duplex venous imaging demonstrated patent left iliac vein interposition graft.

**Conclusion:** Detailed anatomic knowledge as well as communication with the urologist regarding details of this patient's procedure prompted proper work-up of his ominous findings. The surgical decision making regarding this injury was key to a successful outcome in this patient, as there were multiple obstacles including severely limited exposure and the critical decision regarding method of repair. Decision to divide the hypogastric artery allowed a more comprehensive analysis of the etiology. Innovative use of a single limb from a bifurcation graft to interpose the gap remaining after the injured segment was resected also contributed to the success and limb salvage in this patient.

**Keywords:** Prostatectomy; Lymphadenectomy; Computed tomography venogram; Etiology

## Introduction

A patient with a discolored, painful, swollen limb is a concerning clinical finding with a worrisome differential diagnosis. Such findings presenting themselves shortly after another surgical procedure may alter the differential diagnosis, requiring specifics regarding the nature of the procedure as well as detailed pertinent anatomy. This is a case of a 66-year-old male who presented with a bluish-purple lower extremity following a robotic prostatectomy.

## Case Presentation

A 66-year-old male underwent a robot-assisted radical prostatectomy with bilateral pelvic lymphadenectomy in April, 2019. During lymphadenectomy, bleeding was noted on the left side of the pelvis, which was repaired by the urologist with a 4-0 polypropylene (Ethicon Somerville, NJ) suture in a figure-of-eight fashion. Hemostasis was achieved at that point and the remainder of the operation was completed. Immediately post-operatively, patient

complained of left lower extremity swelling and paresthesias without pain. Patient was sent to the intensive care unit for close monitoring. While there, he developed bluish-purple discoloration of his entire left lower extremity associated with pain (Figure 1). On exam, the patient had bluish-purple discoloration and swelling of the left lower extremity extending from the foot to the thigh was noted. He had limited movement in the toes but no sensation to light touch on the dorsum of the left foot. Left lower extremity was warm to touch. Patient had a weak left dorsalis pedis and a weak posterior tibial pulse. A Computed Tomography Venogram (CTV) of the abdomen and pelvis was performed (Figure 2).

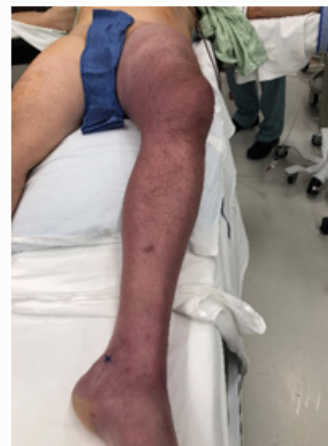

Figure 1: Discoloration of left lower extremity.

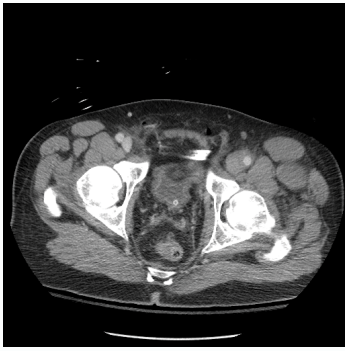**Citation:** Qasawa RN, Hans SS. A Patient with Bluish-Purple lower Extremity Following Robotic Prostatectomy. Am J Surg Tech Case Rep. 2020;1(2):1011.

**Copyright:** © 2020 Ryan N Qasawa

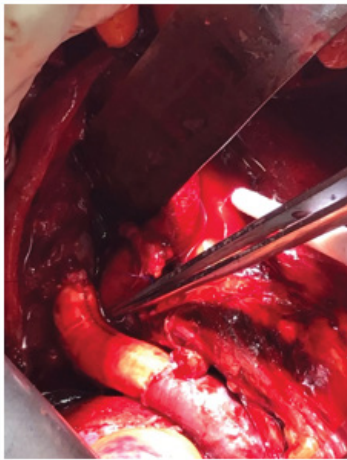
**Publisher Name:** Medtext Publications LLC

**Manuscript compiled:** Oct 19<sup>th</sup>, 2020

**\*Corresponding author:** Ryan N Qasawa, General Surgery Resident, Henry Ford Macomb Hospital, Clinton Township, Michigan, USA, E-mail: rqasawa1@hfhs.org



**Figure 2:** CTV of the pelvis.



**Figure 3:** PTFE interposition graft between left common iliac vein near the junction of external iliac vein extending for 5 cm to mid-external iliac vein.

## Discussion

Our initial differential diagnosis included acute left iliac arterial occlusion, acute left iliac venous obstruction, livedo reticularis, and lymphedema. The signs and symptoms were initially concerning for acute arterial occlusion, given his lower extremity discoloration, paresthesias, and motor weakness of the left foot. However, patient had weak palpable pulses in the affected extremity. Generally, patients with acute arterial occlusion initially complain of sudden onset pain and the limb is cool and pale [1]. Only late in patients with long-standing acute arterial occlusion, bluish-purple discoloration occurs.

In livedo reticularis, there is red, blue, or purple discoloration of the skin in a net-like pattern [2,3]. This finding may be transient or persistent [4]. Potential causes of this finding are numerous, ranging from idiopathic to various systemic and autoimmune disorders. In most cases, it is benign, asymptomatic, and attributed to cold exposure. Occasionally, patients may complain of numbness and tingling [2].

Lymphedema is a chronic condition and does not present acutely. Although lymphoceles are a common complication of pelvic lymph node dissections and may present with swelling [3], most presentations are delayed roughly 3 weeks post-operatively following robotic prostatectomy [5]. Additionally, symptomatic lymphoceles do not present with skin discoloration or paresthesias.

Clinical exam and CTV of the abdomen and pelvis confirmed the diagnosis of left external iliac vein thrombosis. Patient underwent immediate exploration via a midline laparotomy incision extending from symphysis pubis to just above the umbilicus. The left common and external iliac arteries were exposed below the sigmoid colon after division of the Line of Toldt. There was a hematoma obscuring the pelvic vasculature on the left side. Vessel loops were passed around the distal left common iliac vein and distal left external iliac vein, and the area of injury to the iliac vein was exposed. Due to severely limited exposure, control of the common iliac and hypogastric veins required division of the hypogastric artery. The stitches from the repair of the iliac vein injury were removed. Determination was made that a patch repair would not be sufficient, as the vein had less than 10% residual lumen. The injured portion of the vein was resected and an 11 mm limb of a PTFE bifurcation graft was selected and used as a 5 cm long interposition graft between the distal common iliac and the external iliac vein (Figure 3). A 6-0 polypropylene (Ethicon Somerville, NJ) running suture was used for both the proximal and distal anastomoses. Hemostasis was confirmed and the abdomen was closed. Immediately post-operatively, the patient's left lower extremity discoloration and pain improved significantly. Patient was discharged on the twelfth post-operative day. Patient was treated with Apixaban for 6 months. Follow-up duplex venous imaging showed patent left iliac vein interposition graft.

## References

1. Creager MA, Kaufman JA, Conte MS. Acute Limb Ischemia. *N Eng J Med.* 2012;366(23):2198-206.
2. Gibbs M, English JC, Zirwas JM. Livedo reticularis: An update. *J Am Acad Dermatol.* 2005;52(6):1009-19.
3. Loeb S, Partin AW, Schaeffer EM. Complications of pelvic lymphadenectomy: do the risks outweigh the benefits? *Rev Urol.* 2010;12(1):20-4.
4. Sajjan VV, Lunge S, Swamy MB, Pandit AM. Livedo reticularis: A review of the literature. *Ind Dermatol Online J.* 2015;6(5):315-21.
5. Tsaur I, Thomas C. Risk factors, complications and management of lymphocele formation after radical prostatectomy: A mini-review. *Int J Urol.* 2019;26(7):711-6.



