

Case Report

Endovascular Aneurysm Repair (EVAR): A Case Report of an Elderly Male with A Short Neck Abdominal Aortic Aneurysm (AAA) Treated with ALTO Endograft

Sagar K. Kamaraju* and Nicolas J. Mouawad

Department of Vascular & Endovascular Surgery, McLaren Bay Region, USA

Abstract

Abdominal aortic aneurysms cause 1.3% of all deaths among men aged 65-88 years in developed countries. While most treatments use an endovascular approach, they require a proximal neck length of at least 10 mm -15 mm. We detail a case of an 82-year-old male, who presented with an incidental finding of a 6.2 cm infrarenal abdominal aortic aneurysm with a 10.1 mm infrarenal neck. Evaluation on CT angiogram revealed enlarged right lateral wall and enlarged distal aspect of infrarenal aorta with a long bifurcation. This case study demonstrates the importance of the ALTO abdominal stent graft system to treat infrarenal abdominal aortic aneurysm treated with Endovascular Aneurysm Repair.

Introduction

An Abdominal aortic aneurysm (AAA) is a pathological condition with progressive abdominal aortic dilation that predisposes the abdominal aorta to rupture [1]. If left untreated, the aortic wall continues to weaken and becomes unable of withstanding the forces of the luminal blood pressure [2]. The short proximal aortic neck presents a technical challenge for Endovascular Aneurysm Repair (EVAR). Approved endograft devices in the US require a proximal neck length indication of at least 10 mm - 15 mm [3]. However, other devices have been inserted into aneurysms with shorter necks, by using suprarenal fixation devices inserted into necks as short as 5 mm [4]. ALTO offers an innovative sealing option for AAA by including a sealing ring, filled with a polymer, 7 mm from the renal arteries [5].

We present an infrarenal abdominal aortic aneurysm treated with Endovascular Aneurysm Repair (EVAR) using an ALTO abdominal stent graft system.

Case Presentation

We report a case of an 82-year-old male, who presented with an incidental finding of a 6.2 cm infrarenal abdominal aortic aneurysm with a 10.1 mm infrarenal neck. Patient has history of paroxysmal atrial fibrillation, on anti-coagulation, COPD, hypertension, and hyperlipidemia. Initial examination showed a bubbling of the right lateral wall of the infrarenal aorta. Axial CT revealed enlarged right lateral wall and an enlarged distal aspect of infrarenal aorta with a long bifurcation for an aneurysm (Figure 1). Most endografts had to

be excluded, due to a 10 mm - 15 mm infrarenal seal and fixation with no thrombus, calcification, or plaque (Figure 2-4). ALTO Polymer based endograft requires fixation and seal to be separated; while requiring requires an IR7 position (seal site is 7 mm below the renal artery). Fixation was obtained from a 3.5 cm suprarenal stent.

A 35 mm O-ring polymer based endograft was used with two limbs on the left side as it was long into the hypogastric artery to ensure no type I endoleak or aneurysmal degeneration distally (Figure 5). With it being longer than the maximal noted length of 160 mm, two limbs were necessary. Surgical intervention was done using EVAR technique, with the ALTO main body delivery system being introduced over a Lunderquist wire under ultrasound guidance via the common femoral artery in a retrograde fashion, with the upsizing of sheaths. The wires were crossing with themselves, so a ballerina type crossover was used for contralateral gate cannulation. The limbs were offset, with the contralateral limb being 5 mm longer, allowing for easier cannulation and a great seal at the left renal artery (Figure 6).

Coronal CT at 4-month follow-up showed the rings themselves and that the suprarenal stent positioned well at the left renal artery (Figure 7). Despite having calcium or thrombus present, we could use it as part of the seal zone to ensure no Type IA endoleak. We saw a dissociation between the suprarenal stent and the iliac limbs; however, the polymer was still present. Polymer rings looks less radio opaque and continues progressive opacity as time progresses. Similarly, maximum aneurysm diameter gets smaller and continues as time progresses. Despite not being seen, there is fabric between the suprarenal stents and the bilateral iliac stents. The fabric was present with a sealing ring on post-op imaging.

Discussion

The preferred therapeutic option for infrarenal abdominal aortic aneurysm with a short proximal landing zone is open surgical repair with a custom-made fenestrated stent graft [6]. A broad literature search revealed several case reports of ALTO abdominal stent graft system in patients with infrarenal neck indication above 7 mm [7]. However, Gregory, et al. [8] reported that an ALTO device in patients with more hostile aortic anatomies remains to be seen [8]. That is what was accomplished to prove.

Citation: Kamaraju SK, Mouawad NJ. Endovascular Aneurysm Repair (EVAR): A Case Report of an Elderly Male with a Short Neck Abdominal Aortic Aneurysm (AAA) Treated with ALTO Endograft. *Am J Surg Case Rep.* 2024;5(6):1135.

Copyright: © 2024 Sagar K. Kamaraju

Publisher Name: Medtext Publications LLC

Manuscript compiled: Jun 05th, 2024

***Corresponding author:** Sagar K. Kamaraju, Department of Vascular and Endovascular Surgery, McLaren Bay Region, USA

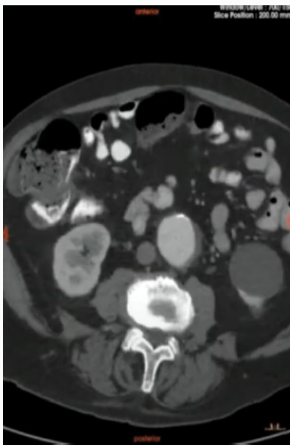


Figure 1: Pre-OP Axial CT.

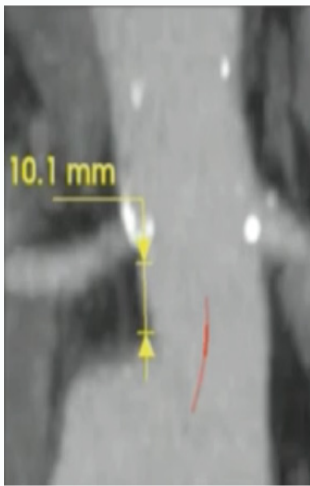


Figure 2: Aortic Neck Length.

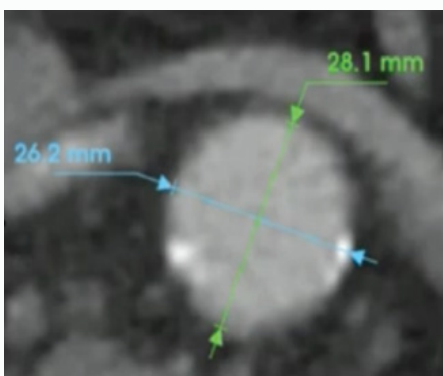


Figure 3: Adaptive Sealing Zone.

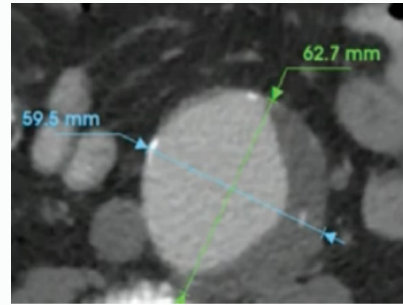


Figure 4: Max Diameter of AAA.

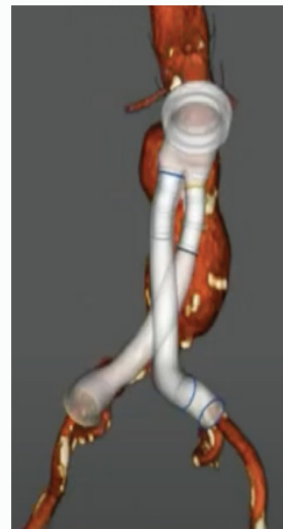


Figure 5: Case Plan ALTO.

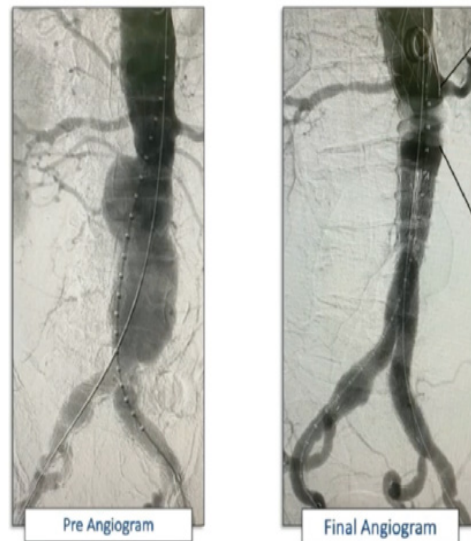


Figure 6: Index Procedure Angiogram.

The case presented herein is unique due to the short infrarenal neck indication of 10.1 mm with thrombus and calcification being present. Similar cases of Short Neck Abdominal Aortic Aneurysm have used a fenestrated stent-graft. However, there was one type II endoleak, two cardiac complications, three urinary complications, and one occlusion of the renal artery [9], we have seen no complication in the nine months post-op. ALTO treats any aneurysm which is labeled

as 7 mm infrarenal neck indication. We were able to use the ALTO abdominal stent graft system for use on a shorter neck with thrombus and calcification present. Furthermore, we don't have to worry about migration due to the suprarenal stents being present. The separation

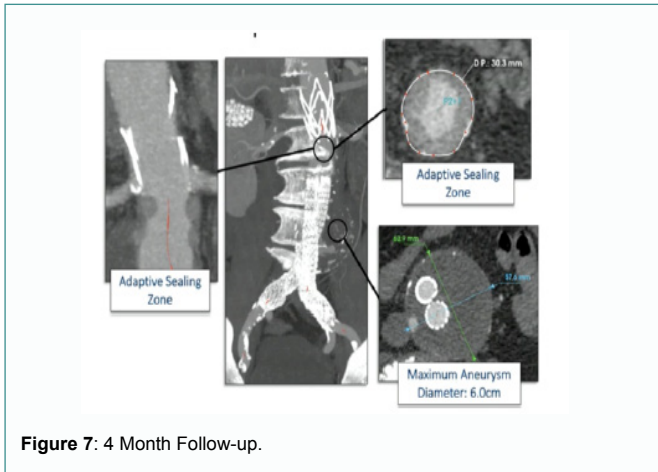


Figure 7: 4 Month Follow-up.

of seal and fixation sites allowed for the treatment of a variety of aneurysms of label.

Conclusion

It is important for vascular and endovascular surgeons to be aware of the possibility of Endovascular Aneurysm Repair in patients with a short proximal aortic neck. We demonstrated the efficacy of the ALTO abdominal stent graft system for use in patients with infrarenal neck indications below 7 mm.

References

1. Haque K, Bhargava P. Abdominal Aortic Aneurysm. *Am Fam Physician*. 2022;106(2):165-72.
2. Kuivaniemi H, Ryer EJ, Elmore JR, Tromp G. Understanding the pathogenesis of abdominal aortic aneurysms. *Expert Rev Cardiovasc Ther*. 2015;13(9):975-87.
3. MacLean AA, Katzen BT. The short proximal AAA neck. *Endovascular Today*. 2006.
4. Jackson BM, Fairman RM. Suprarenal fixation is required for EVAR. *Endovascular Today*. 2012.
5. de Donato G, Pasqui E, Sirignano P, Talarico F, Palasciano G, Taurino M, et al. Endovascular abdominal aortic aneurysm repair with ovation alto stent graft: protocol for the ALTAIR (ALTO endograft Italian Registry) study. *JMIR Res Protoc*. 2022;11(7):e36995.
6. Malkawi AH, Thompson MM, Loftus IM. Standard EVAR for the 10-mm neck. *Endovascular Today*. 2013.
7. Efthymiou FO, Tsimpoukis AL, Papatsirou MA, Kouri NK, Papadoulas SI, Nikolakopoulos KM, et al. Endovascular juxtarenal aortic aneurysm repair using the ALTO abdominal stent graft system: The first case series. *Vasc Specialist Int*. 2022;38:17.
8. Gregory M, Metcalfe M, Steiner K. Profile of the Ovation ALTO abdominal stent graft for the treatment of abdominal aortic aneurysms: overview of its safety and efficacy. *Expert Rev Med Devices*. 2021;18(12):1145-53.
9. Verhoeven ELG, Prins TR, Tielliu IFJ, van den Dungen JJAM, Zeebregts CJAM, Hulsebos RG, et al. Treatment of short-necked infrarenal aortic aneurysms with fenestrated stent-grafts: short-term results. *Eur J Vasc Endovasc Surg*. 2004;27(5):477-83.