

Clinical Image

Pinworms (*E.vermicularis*) Mimicking Acute Appendicitis

Amina Akhtar*, Amari Thomas and Sridhar Dharamavaram

Department of Trauma, Queens Medical Centre, Nottingham, UK

Clinical Image

A 14-year-old boy who presented with severe intermittent central abdominal pain was admitted to the emergency department. The pain was associated with a two-day history of diarrhoea and vomiting. Of important note, he suffered with a similar pain earlier that year, which was diagnosed as IBS by his general practitioner. On examination there was moderate periumbilical tenderness, without guarding and negative Mc Burney sign. Blood laboratory tests were unremarkable and the appendix was not visualized on the ultrasound. After twenty-four hours of observation, symptoms had worsened and he was subsequently diagnosed with atypical appendicitis. The patient was booked for diagnostic laparoscopy +/- appendectomy. The appendix was found to be somewhat injected intra-operatively and during removal pinworms were seen at the base (Figure 1). The appendectomy was completed and specimens were sent for histology, which confirmed the presence of pinworms (Figure 2). Post-operatively the patient was treated with Mebendazole and soon discharged with treatment recommended for the entire household.

Pinworms are a parasite of the roundworm family *E. vermicularis* and are the most common worm in the UK. Up to 40% of school children will suffer with this parasite infection at some time in their lives [1]. Carriers of the parasite are often asymptomatic, though they may suffer with anal pruritis and nocturnal irritation. The infection is spread either directly or indirectly *via* the faeco-oral route often *via* the parasite's eggs. The eggs may survive outside the body for two weeks [2]. Following ingestion, the eggs hatch in the small intestines and mature in roughly six weeks. Right iliac fossa pain and anorexia may mimic appendicitis in these patients, but inflammatory markers are often lower [3]. Studies have reported a mean CRP of 22 and white blood cells of 11.7 [4], whilst 77% of patients have no raise in inflammatory markers [5]. NICE guidelines (based on the South Australian perinatal practice guidelines [1], which state that examining the perianal area for excoriation and secondary bacterial infections is essential. Additional advice includes applying transparent adhesive tape to the perianal skin to look for specimen. Once confirmed macroscopically, the first line anthelmintic treatment is Mebendazole.

Citation: Akhtar A, Thomas A, Dharamavaram S. Pinworms (*E.vermicularis*) Mimicking Acute Appendicitis. *Ann Med Case Rep.* 2020; 2(1): 1010.

Copyright: © 2020 Amina Akhtar

Publisher Name: Medtext Publications LLC

Manuscript compiled: Mar 06th, 2020

***Corresponding author:** Amina Akhtar, Department of Trauma, Queens Medical Centre, Nottingham, UK, E-mail: amina_akhtar1993@hotmail.com

EV was found in 3.8% of 287 paediatric emergency appendectomies in a large UK paediatric hospital in 2018 [4]. In these patient's surgery is associated with unnecessary risk and potential morbidity, but the opportunity cost of operating must also be considered. The median cost of laparoscopic appendectomy, equipment and inpatient cost is £1,617 [6], whereas the average Mebendazole course costs under £3 [7].

Awareness of EV, in combination with a few additional and simple investigations, could help reduce misdiagnosis in this patient group and mitigate both the risks and cost of avoidable surgery.

Learning points/take home messages are

- Pinworm/ EV infection should be considered in all paediatric patients presenting with abdominal pain, and it may mimic the symptoms of acute appendicitis.
- Asking about nocturnal irritation and anal pruritis, in addition to examining the perianal area for excoriation could help to avoid misdiagnosis.
- If examination and history has not been sufficient to formulate a diagnosis; a mild inflammatory response on laboratory results and adhesive tape to the perianal skin to look for specimen can aid diagnosis.

Patient's Perspective

The patient's mother told that "Initially I assumed that the pinworm infection was caused by uncleanness or due to poor hygiene, so I started to sanitizemy son's and my hands more frequently. After having a discussion with the doctor at a follow up session, I was explained how the infection can spread from school or play areas and not necessarily due to my fault. After this was communicated to me, I felt reassured and my sense of guilty had been eased, it was a very important message to me".

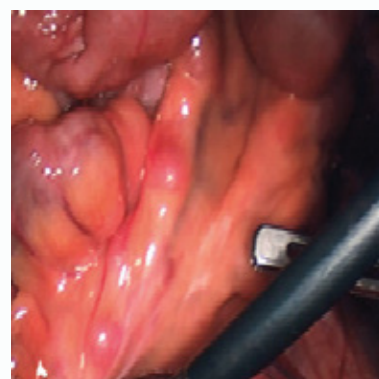

Figure 1: Image of normal appearing appendix.

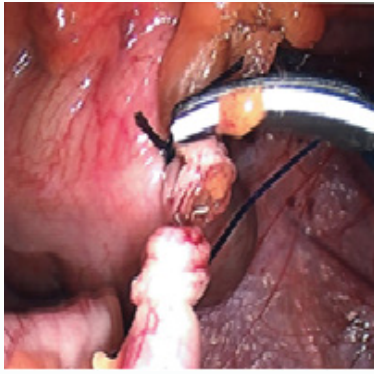


Figure 2: Image of pinworm.

References

1. National Institute for Health and Care Excellence, CKS. Threadworm. UK: NICE; 2018.
2. Public Health Dept, NHS Borders. Threadworms: important information. Melrose: NHS Borders; 2014.
3. Turkington C, Ashby BL. The encyclopaedia of infectious diseases. 3rd ed. New York: Facts on File Inc; 2007. p. 236.
4. Zouari M, Louati H, Abid I, Trabelsi F, Ben Dhaou M, Jallouli M, et al. Enterobius vermicularis: A Cause of Abdominal Pain Mimicking Acute Appendicitis in Children. A Retrospective Cohort Study. Arch Iran Med. 2018;21(2):67-72.
5. Lala S, Upadhyay V. Enterobius vermicularis and its role in paediatric appendicitis: protection or predisposition? ANZ J Surg. 2016;86(9):717-9.
6. Needham PN, Laughlan KL, Botterill ID, Ambrose NA. Laparoscopic Appendicectomy: Calculating the Cost. Ann R Coll Surg Engl. 2009;91(7):606-8.
7. National Institute for health and Care Excellence, BNF. Mebendazole Medicinal Forms. UK: NICE; 2019.